

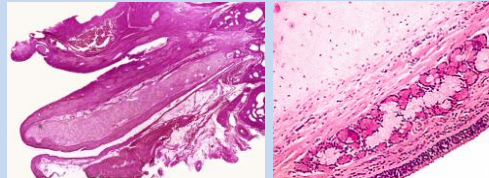
Tubenventilationsstörung

N. Gürtler
HNO-Universitätsklinik
Universitätsspital Basel

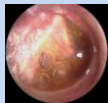

Physiologic Function

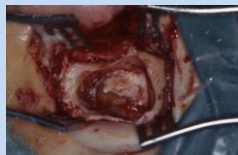
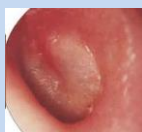
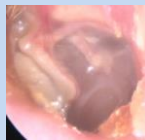
- 1) ... Pressure regulation middle ear
- 2) ... Protection against pathogenic micro-organisms of the nasopharynx
- 3) ... Clearance of middle ear
- 4) ... Protection from vocal sounds



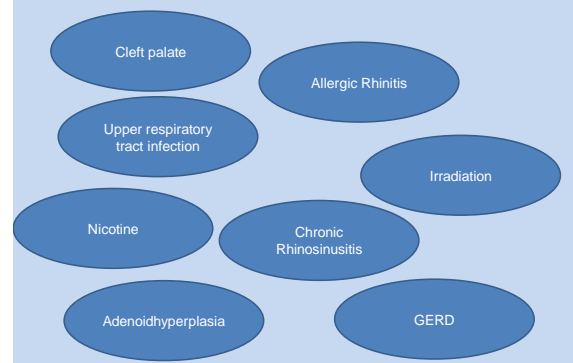
Chronic Eustachian Tube Dysfunction



Chronic serous otitis media
Tympanic retraction
Perforation/Cholesteatoma
Pressure equalization problems



Etiology



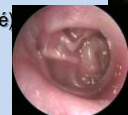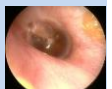Symptoms

Symptoms
Hearing Loss
Tinnitus
Pressure
Vertigo
Problems with pressure equalization
Autophony
Ear pain

Evaluation

Clinical Tests

- Earmicroscopy
- Serous otitis media
- Retraction (Grading according Sadé)
- Valsalva and Toynbee
 - Negative in 1/3 healthy individuals
- Politzer



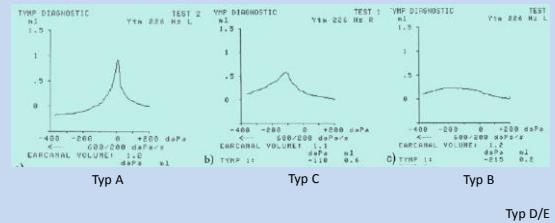
Apparative examinations

1	Manometric testing
2	Endoscopic measurement
3	Acoustic testing
4	Radiologic imaging
5	Nuclear medicine testing
6	Others

+??? Pure-tone-audiogramm

Manometric testing I

Tympanometry



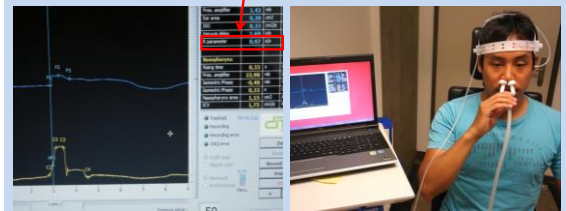
Chronic serous otitis media: Sensitivity/Specificity 80-90%

Manometric testing II

- Forced response test
- Aspiration-Deflation-test
- Nine-Step-Inflation-Deflation-Test
- Mod. Inflation-Deflation-Test
- Pressure chamber
- **Tubomanometry modified (Estève)**

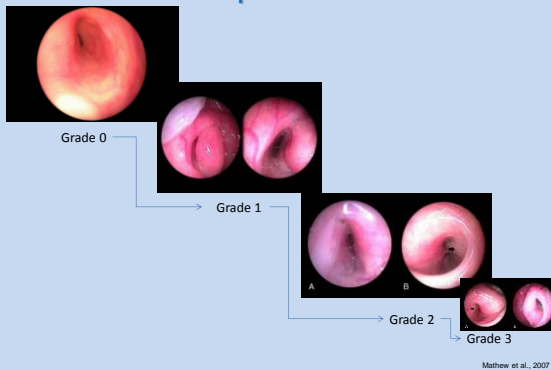
Tubomanometry

R-value



- Pressure measurement external ear canal, nasal pressure applicator
- Defined pressure during swallowing (30, 40, and 50 mbar)
- Measurement of pressure change in external ear canal and Nasopharynx

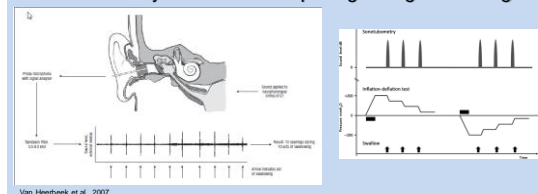
Endoscopic measurement



Acoustic testing

Sonotubometry:

- Measures function with sounds
- Sound applicator in nose, Microphone in external ear canal
- Remember function of eustachian tube: protection from sound transmission!
- 10-20% healthy individuals: no opening during swallowing

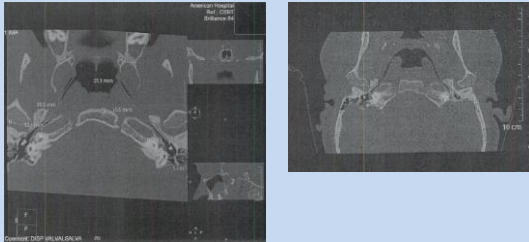


Radiologic imaging

The Laryngoscope
© 2014 The American Laryngological,
Rhinological and Otolaryngological Society, Inc.

Visualization of the Eustachian Tube Lumen With Valsalva Computed Tomography

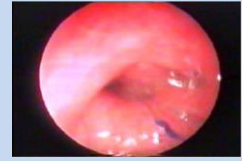Muazz Tarabichi, MD; Murtaaza Najmi, MD



Others

Drainage of middle ear

- Fluorescein / Methylene blue
- Saccharine in middle ear



Prasad et al. 2009, Otolaryngol Head Neck Surg

Optotensometry

Electromyography

Eustachian Tube Dysfunction Questionnaire

ETDQ-7 deutsch						
Beschwerden in den letzten 4 Wochen an den meisten Tagen						
1. Druckgefühl im Ohr	1	2	3	4	5	6
2. Schmerzen in den Ohren	1	2	3	4	5	6
3. Gefühl, die Ohren seien verstopft oder „unter Wasser“	1	2	3	4	5	6
4. Ohrenbeschwerden im Rahmen von Erkältungen und Nebenhöhlenentzündungen	1	2	3	4	5	6
5. Klirrende oder knallende Geräusche in den Ohren	1	2	3	4	5	6
6. Klingeln in den Ohren	1	2	3	4	5	6
7. Gefühl, das Hören sei dumpf	1	2	3	4	5	6

Sensitivity/Specificity: > 90%

Cut-off value: ≥ 14.5 points

Schröder et al., 2014

Eustachian Tube Score-7

Symptom/Finding	2 Points	1 Point	0 Points
Clicking sound when swallowing	Always	Occasionally	Never
Positive subjective Valsalva	Always	Occasionally	Never
Objective Valsalva	Immediate	Weak and slow	Negative
Tympanometry	A	C	B
TMM 30 mbar ^[11, 12]	R ≤ 1	R > 1	No R
TMM 40 mbar ^[11, 12]	R ≤ 1	R > 1	No R
TMM 50 mbar ^[11, 12]	R ≤ 1	R > 1	No R

Eustachian tube score-7 ranging from 0 to 14 points.

TMM = tubomanometry.

Sensitivity/Specificity: > 90%

Cut-off value: <7 points

Schroeder et al., 2015, Laryngoscope

Therapy



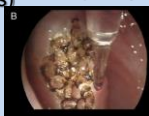Non-surgical

topical Steroids (4-6wks)

PPI (4-6wks)

Surgical

Laser-tuboplasty



Grommets

Eustachian tube balloon-dilation

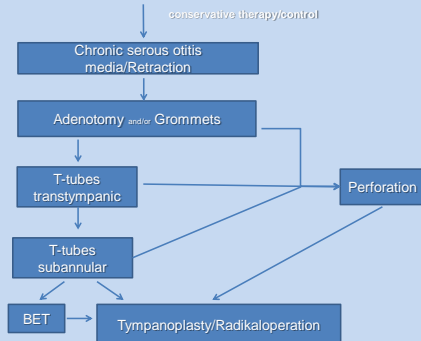
Price et al.

Llewellyn et al., 2014

Evidence-Based Medicine


Intervention	EBM
Topical steroids	No
Pressure equalization devices	No (Yes for Politzer)
Decongestants/Antihistamines	No
Laser tuboplasty	No
Balloon dilation	No
Grommets	No
Others	No

Chronic eustachian tube dysfunction in childhood: Basler Schema

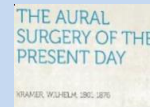


Eustachian tube ballond dilatation: history

1838



ca. 1850



2010

Balloon Dilation Eustachian Tuboplasty: A Feasibility Study

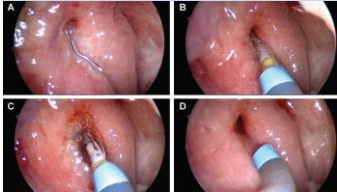
*Thorsten Ockermann, *Ulf Reineke, †Tahwinder Upile,
*Jörg Ebmeyer, and *Holger H. Sudhoff

Eustachian tube balloon-dilatation: 2 products

Ballonkatheter Spiggle&Theiss:

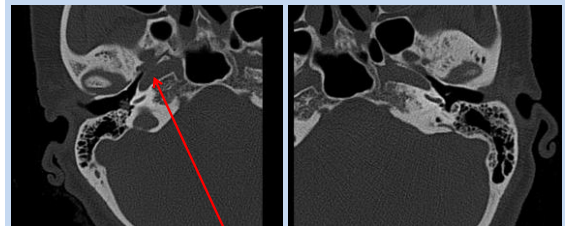


Sinus balloon catheter Acclarent:

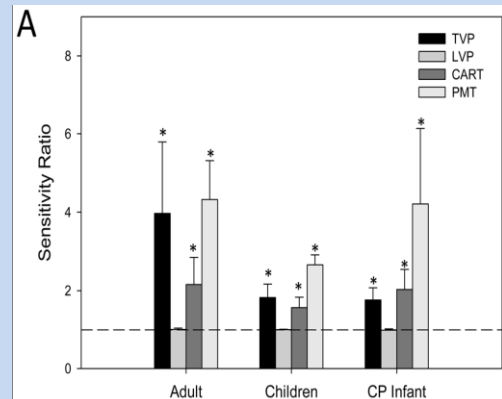
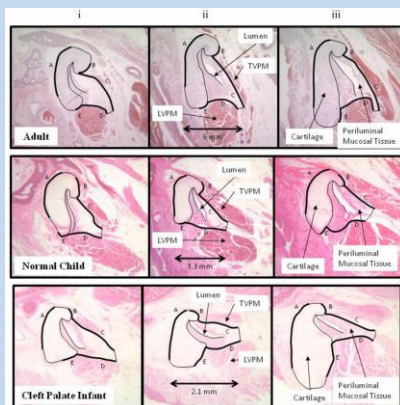


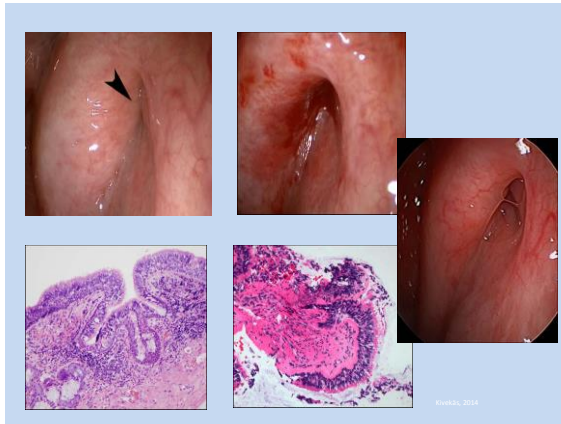
F-70 guide catheter (Acclarent, Menlo Park, CA, USA) soft, flexible Relieva Vortex (7-mm wide and 16-mm long balloon catheter (Acclarent))

Computertomographie



Dehiszenz





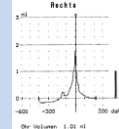
Patulous Eustachian Tube

Symptoms:

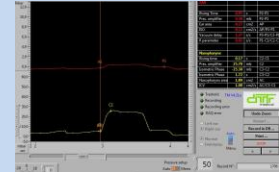
- Hears own voice (Autophony)
- Hears own breathing

Diagnostic:

- Fiberoptic (Epi-)pharyngoscopy
- Tympanometry (long stretch)

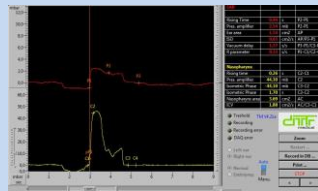
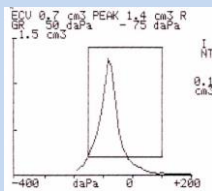
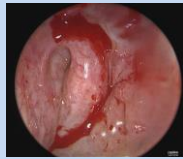

- Tubomanometry



Therapy

- 1)... Wait!
- 2)... Restylane-Injection
- 3)... Tuboplasty (Voximplant)



Literature

1. Funktionsuntersuchungen der Tuba Eustachii. DiMartino E et al., HNO 2004
2. Systematic review of the limited evidence base for treatments of Eustachian tube dysfunction: a health technology assessment. Norman G et al., Clin Otolaryngol 2014
3. Bringt die Ballondilatation den erhofften Durchbruch bei Tubenfunktionsstörungen – auch bei Kindern?. Pau H, HNO 2015